

## **Autogenous Cartilage Grafts in Primary Rhinoplasty in the Non-Caucasian Population**

ABD AL-AZIZ H.A. AHMAD, M.D. and IMAN AL-LEITHY, M.D.

*The Department of Plastic Surgery, Faculty of Medicine, Ain Shams University.*

### **ABSTRACT**

Rhinoplasty was performed by the open technique on 22 non-Caucasian patients. A total of 22 cartilage grafts were applied primarily in 15 of them (68.2%). The grafts were applied in the nasal tip (54.5%), dorsum (36.4%) and columella (9.1%). The indications for cartilage grafting were poor definition and inadequate projection of the nasal tip, weak medial crura and depressed nasal dorsum, including saddle deformity. The graft donor sites were the nasal septum (53.3%), the ear concha (46.7%) and the costal cartilage (6.7%). Controllable unsatisfactory results occurred in 20% of cases and were unrelated to the grafting procedure. Graft resorption, displacement and significant warping were not reported in the 6-18 month follow up period. The results of this study indicate that augmentation of the nasal framework is frequently required in primary rhinoplasty. Autogenous cartilage is the material of choice for this purpose because it is safe to use and easy to harvest in sufficient amounts from both nasal and extranasal donor sites.

### **INTRODUCTION**

Aesthetic rhinoplasty developed in last century was a reduction operation. Its indiscriminate application resulted in many amputated noses as a result of resections of the nasal osteo-cartilagenous framework [1]. The North American and European literature on rhinoplasty is strongly oriented toward the anatomy of Caucasian nose. However, there are anatomical differences between Caucasian and non-Caucasian noses [2,3]. These dictate variations in the surgical technique in non-Caucasians in the form of augmentation of parts of the nasal framework by a suitable grafting material or an implant to avoid exchanging one deformity for another [4]. In this paper, we describe our experience with the use of autogenous cartilage grafts from different donor sites in primary augmentation of the nasal osteocartilagenous framework.

### **PATIENTS AND METHODS**

This study was done on 22 non-Caucasian patients that we operated upon in the period from

January, 2002 to December, 2003. Primary cartilage grafts were applied in 15 patients. Of these, 7 patients were Arabs, including Egyptians, 6 were Asians and 2 were Africans. 2 were males (13.3%) and 13 were females (86.7%). Their ages ranged between 17 and 30 years (average 22.13 years). The postoperative follow up period ranged between 6 and 18 months.

All cases were subjected to external and internal nasal examination before surgery. The expectations of the patient from the procedure were discussed before the operation. According to the preoperative anatomical findings, the indications for cartilage grafting were:

- Poor nasal tip definition and inadequate projection in 12 patients.
- Weak medial crura with inadequate columellar support to the nasal tip in 2 patients.
- Decreased projection of the nasal bridge, including saddle deformity in 8 patients.

All cases were done under general anesthesia. We used the open rhinoplasty technique for exposure of the nasal osteocartilagenous framework and application of autogenous cartilage grafts [5].

The cartilage graft donor sites were the nasal septum, the ear concha or the costal cartilage. The recipient sites were the nasal tip, columella and the nasal dorsum (Fig. 1). Septal cartilage was used for constructing on-lay tip grafts, columellar struts and for minor to moderate dorsal augmentation. The ear conchal cartilage was used for on-lay tip grafting and the rib cartilage was used as a dorsal graft in cases of severe dorsal depression (Table 1). Cartilage graft harvesting, preparation and application into different recipient sites were already described [5,6].

Results were evaluated as regards the aesthetic

outcome and the incidence of complications. Subjectively, the aesthetic outcome was considered excellent, good, fair, or poor according to the surgeon's evaluation and the patient's point of view [7]. Objectively, the outcome was documented by standard pre- and post-operative photographs including anterior, basal and lateral views [8]. Surgical complications of the procedure and technical errors were recorded.

## RESULTS

Cartilage grafts were applied in primary rhinoplasty for 15 non-Caucasian patients (Figs. 2,3). Transient mild hemorrhage and ecchymosis in the paranasal and periorbital areas were encountered in patients requiring osteotomies of the nasal bones (4 cases). The most common complication was prolonged postoperative edema of the nasal tip area. This occurred in 12 cases (80%) and persisted for at least 10 weeks. Scars of the transcolumellar incision and alar reduction were conspicuous for 6-12 weeks postoperatively and became less apparent later, without keloid or hypertrophic scar formation. None of our patients had serious hemorrhage requiring blood transfusion, infection, pneumothorax, septal hematoma or septal perforation.

The aesthetic outcome was considered good to excellent in 10 cases (66.7%) and fair to poor in 5 cases (33.3%). Unsatisfactory outcomes were due to technical errors. The most common of these was asymmetry of the nostrils, which occurred in two cases (13.3%). Supra-tip deformity occurred in one case (6.7%), stair step deformity in another case (6.7%) and undercorrection of depression of

the nasal bridge in a third case (6.7%). We did not have any case of graft resorption or displacement (Table 2). Unsatisfaction due to inability to camouflage the thick skin in the tip area was not considered because it is beyond the surgeon's control.

Table (1): Indications and recipient sites of cartilage grafts in primary rhinoplasty.

Indication	Graft recipient site					
	Nasal tip		Columella		Nasal dorsum	
	No.	%	No.	%	No.	%
Inadequate tip projection	8	53.3				
Poor tip definition	4	26.7				
Weak medial crura			2	13.3		
Depressed nasal dorsum					6	40
Saddle nose deformity					2	13.3
Total	12	80	2	13.3	8	53.3

N.B.: The number of patients n = 15.

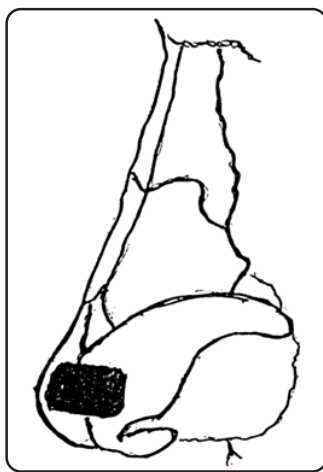
Each of 7 patients received 2 grafts and one had grafts from two donor sites.

Table (2): Complications and unsatisfactory results of primary rhinoplasty in patients requiring cartilage grafts.

Complications			Unsatisfactory results		
Severe hemorrhage	0	0%	Asymmetric alar base resection	2	13.3%
Infection	0	0%	Graft malposition	0	0%
Prolonged edema in the nasal lobule	12	80%	Graft displacement	0	0%
Keloidal scarring	0	0%	Graft resorption	0	0%
Septal perforation	0	0%	Stair step deformity	1	6.7%
Deformity of the auricle	0	0%	Inadequate dorsal projection	1	6.7%
Pneumothorax	0	0%	Supra tip deformity	1	6.7%

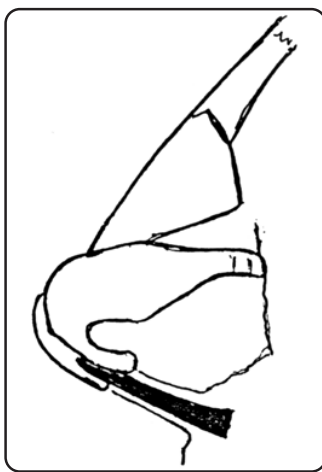
N.B.: The number of patients n = 15.

Fig. (1): Diagrams showing different types of primary cartilage grafts.



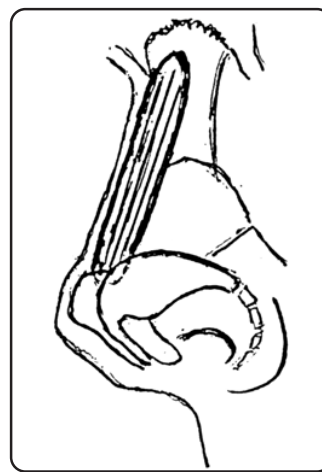
On-lay tip graft

Fig. (1-A): On-lay tip graft.



Columellar strut graft

Fig. (1-B): Columellar strut graft (From Rohrich and Muzaffar, 2000).



Dorsal graft

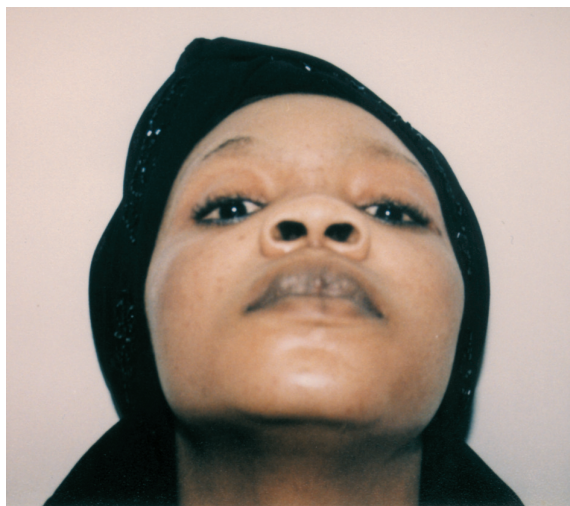Fig. (1-C): Dorsal graft (From Ortiz-Monasterio and Molina, 1994).



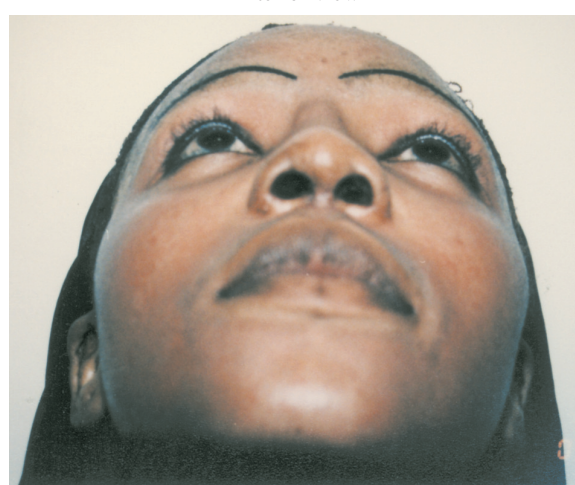
Anterior view



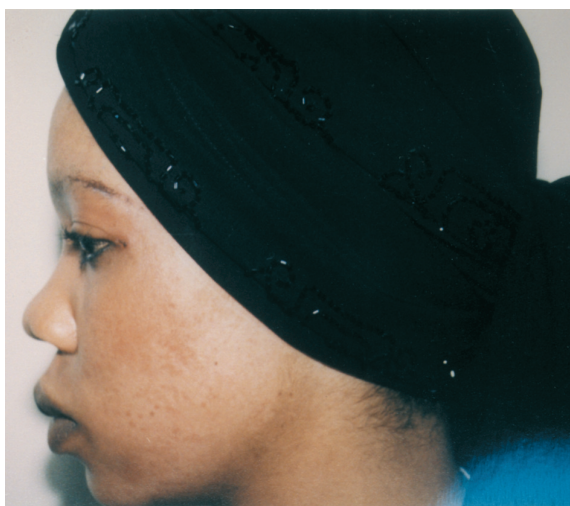Anterior view



Basal view

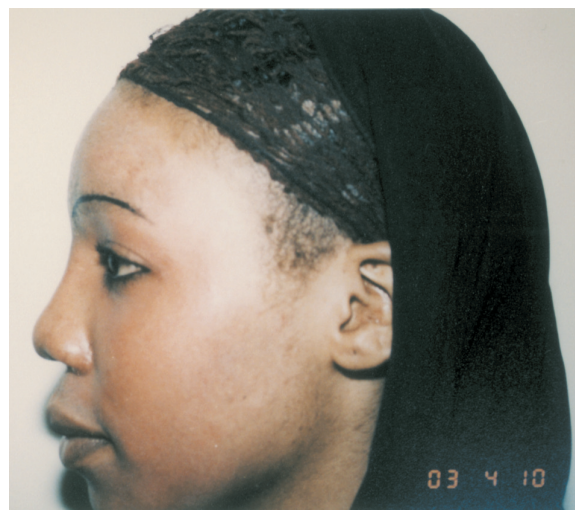

Basal view



Lateral view

(A)  
Preoperative views.



Lateral view

(B)  
Postoperative views.

Fig. (2): Preoperative anterior, basal and lateral views of a 17-year-old African patient with saddle nose deformity (a). Postoperative views of the same patient after applying dorsal graft from the rib cartilage, interdomal suture and alar base resection (b).





Anterior view



Basal view

(A)  
Preoperative views.

Anterior view



Basal view

(B)  
Postoperative views.

Fig. (3): Preoperative anterior and basal views of a 17-year old, thin-skinned Arabic patient with a broad nasal tip and deviated septum (a). Postoperative views for the same patient after septorhinoplasty and application of a columellar strut and a tip cartilage grafts from the nasal septum (b).

## DISCUSSION

Non-Caucasian nose is anatomically different from Caucasian nose [3]. Removal of a dorsal hump is carefully done and may not be indicated in African and Asian patients [2,8]. The depressed nasal dorsum in those patients requires dorsal augmentation rather than osteotomies [3,9]. The nasal septum is small and represents a limited source of grafting material [10]. The thick, inelastic skin does not drape well over the nasal framework [6]. These anatomical characteristics make aesthetic

rhinoplasty in non-Caucasians problematic and primary augmentation by a graft or an implant necessary. However, there are variations of this structural pattern due to intermarriage and mixed racial and genetic influence like in Arabs and North Africans [2]. These variations were reflected technically on dealing with the nasal dorsum. Osteotomies for hump removal or narrowing the nasal framework were done for 57.1% and dorsal augmentation was required in 21.4% of Arabs, including Egyptians. Nasal osteotomies were done in 12.5% and dorsal augmentation was required in

62.5% of African and Asian patients. Primary cartilage grafting was needed in 50% of Arabs and in all Asian and African patients (100%).

Alloplastic implants and autogenous grafts were used for augmentation of the nasal framework or filling nasal defects [2,11,12]. Alloplastic implants are available without an additional surgical procedure and are well tolerated when placed under adequate, unscarred soft tissue cover [2]. However, their use is unjustified in primary rhinoplasty because of their unacceptable rate complications [13]. Autogenous bone can be obtained in large volumes for major nasal defects [7,14,15,16]. Bone graft needs proper fixation and wide contact with recipient bone for revascularization and incorporation. Resorption may occur because of infection or poor contact with bone [7]. Autogenous cartilage is easy to obtain and carve. It does not require contact with bone and does not resorb unless the procedure is complicated by infection [17,18]. The main problem with cartilage grafting is warping which can be minimized by sticking to the principles of balanced cross-sectional carving and avoiding longitudinal stress on the graft by creation of an adequate recipient pocket [19,20].

Selection of the cartilage graft donor site depends on the recipient site and the size of the defect. The nasal septum is the cartilage graft donor site of choice because it is available in the same operative field [6]. Cosmetic patients may not accept harvesting material from extranasal donor sites. We used it for tip, strut and dorsal grafting in 53.3% of cases. We used the ear concha in 50% of cases requiring tip grafts because it is easy to harvest with minimal donor site morbidity and needs minimal or no carving. We did not use it for columellar strut or dorsal grafting, except in one case with small septum, because of its flaccid, asymmetric and convoluted structure [21]. Rib cartilage was used for dorsal augmentation in one case of saddle deformity because large volume and length were needed and the septum was small [10,22]. We used the fifth costal cartilage because of its acceptable donor site scar. An alternative is the ninth floating rib, which has the advantage of being straight [5]. Warping was minimized by symmetrical carving and by the use of a large graft with a substantial cross section [22].

It was estimated that cartilage grafts were applied in 40% of cases of primary aesthetic rhinoplasty. Of these, 56.8% were columellar struts, 33.5% were tip grafts and 5.4% were dorsal grafts [6]. A recent study showed that the number of patients receiving cartilage grafts increased from

94% to 100%. Graft recipient sites averaged 17% in the columella, 41% in the tip and 31% in the dorsum [23]. Dorsal augmentation was felt necessary in 60% of Negro and Asian patients [8]. In our study, primary cartilage grafts were applied in 68.2% of cases. Columellar struts were done in 9.1% of these cases; tip grafts in 54.5% and dorsal augmentation in 36.4% of them. 7 patients received primary cartilage grafts in 2 sites. It had been reported that only 10-15% of rhinoplasties require alar base resection [24]. In our study, alar base resection was done for 54.5% of our cases. Variations in the need for primary cartilage grafts, dorsal augmentation and alar base resection, are explained by the genetic and racial characteristics of our patients population.

Distinction had been made between unsatisfactory results due to controllable technical errors and complications of aesthetic rhinoplasty [25]. It was estimated that 5-10% of rhinoplasty patients require correction of secondary deformities, depending on the surgeon's experience [25,26]. The incidence of re-operation with the use of autogenous cartilage was found to increase in one study and to decline in another [21,23]. In our study, the incidence of unsatisfactory results that required correction by a secondary procedure was 33.3%. If cases requiring minor correction of asymmetric alar base resection were excluded, 3 of our grafted patients needed re-operation (20%). These included supratip deformity in a male patient with a huge nose, a case of stair-step deformity due to improper lateral osteotomies and a case of under-correction of dorsal depression. In the last patient, dorsal graft was constructed from the conchal cartilage. The nasal septum was small and the patient refused harvesting costal cartilage graft. None of these was due to cartilage grafting. The shape of the nose was maintained and the cartilage grafts were palpable during the follow up period, indicating absence of graft resorption. When creation of a pocket for a tip or a dorsal graft was impossible because of wide undermining of the nasal skin, fixation of the graft by buried or a pullout suture was necessary to avoid displacement [6,27]. Malpositioning of the on-lay tip graft is much less than that of the shield-type graft [21]. The only costal cartilage graft we used for dorsal augmentation did not show significant warping in the follow up period. The most common complication was prolonged post-operative edema in the tip area due the thick skin and the effects of the transcolumellar and alar base resection incisions. In some cases, the effects of cartilage grafting on the nasal framework were not striking because of the thick, inelastic skin.

## REFERENCES

- 1- Ortiz-Monasterio F. and Molina F.: Augmentation techniques. In: Ortiz-Monasterio F. and Molina F. (eds.). *Rhinoplasty*. W.B. Saunders Company, Philadelphia, London, Toronto, Montreal, Sydney, Tokyo. Chapter 4, p 43, 1994.
- 2- Rees T.D.: Nasal plastic surgery in the Negro. *Plast. Reconstr. Surg.*, 43: 13, 1969.
- 3- Falces E., Wesser D. and Corney M.: Cosmetic surgery of the non-caucasian nose. *Plast. Reconstr. Surg.*, 45: 317, 1970.
- 4- Sohn S.A.: Rhinoplasty. In: Sohn S.A. (editor). *Fundamentals of aesthetic plastic surgery*. Williams and Wilkins. Baltimore-London-Los Angeles-Sydney. Chapter 6, p 55, 1987.
- 5- Rohrich R.J. and Muzaffar A.R.: Primary rhinoplasty. In: Guyuron B. and Wilkins E.G. (eds.). *Plastic surgery: Indications, operations and outcomes*. Mosby, Inc. St. Louis, London, Philadelphia, Sydney, Toronto. Volume 5, Chapter 146, p 2631, 2000.
- 6- Ortiz-Monasterio F., Olmedo A. and Oscoy L.O.: The use of cartilage grafts in primary aesthetic rhinoplasty. *Plast. Reconstr. Surg.*, 67: 597, 1981.
- 7- Wheeler E.S., Kawamoto H.K. and Zarem H.A.: Bone grafts for nasal reconstruction. *Plast. Reconstr. Surg.*, 69: 9, 1982.
- 8- Matory W.E. and Falces E.: Non-Caucasian rhinoplasty: A 16-year experience. *Plast. Reconstr. Surg.*, 77: 239, 1986.
- 9- Scrimshaw G.C.: Optical illusion in plastic surgery. *Plast. Reconstr. Surg.*, 35: 96, 1965.
- 10- Larrabee W.F. and Nishioka G.L.: Special considerations in rhinoplasty. In: Bailey B.J., Calhoun K.H., Deskin R.W., Johnson J.T., Khout R.I., Pillsbury H.C. and Tardy M.E. (eds.) *Head and neck surgery-Otolaryngology*. Lippincott-Raven Publishers, Philadelphia-New York. Volume 2, Chapter 179, p 2635, 1998.
- 11- Godin M.S., Waldman S.R. and Johnson C.M.Jr.: The use of expanded polytetrafluoroethylene (Got-Tex) in rhinoplasty: A 6-year experience. *Arch. Otolaryngol. Head Neck Surg.*, 121: 1131, 1995.
- 12- Colton J.J. and Beekhuis G.J.: Use of Mersilene mesh in nasal augmentation. *Facial. Plast. Surg.*, 8: 149, 1992.
- 13- Sheen J.: A clinical assessment of alloplastic material in secondary rhinoplasty. In: Rees T.D., Baker D.C. and Tabbal N. (eds.). *Rhinoplasty: Problems and controversies*. The C.V. Mosby Company. St. Louis, Washington D.C. and Toronto. Chapter 43, p 384, 1988.
- 14- Jackson I.T., Smith J. and Mixter R.C.: Nasal bone grafting using split skull grafts. *Ann. Plast. Surg.*, 11: 533, 1983.
- 15- Daniels R.K.: Rhinoplasty and rib grafts: Evolving a flexible operative technique. *Plast. Reconstr. Surg.*, 94: 597, 1996.
- 16- Farina R. and Villano J.B.: Follow up of bone grafts to the nose. *Plast. Reconstr. Surg.*, 48: 251, 1971.
- 17- Guerrerosantos J.: Temporoparietal fascia grafts in rhinoplasty. *Plast. Reconstr. Surg.*, 74: 465, 1984.
- 18- Escobar S.P., Marquez D.F., Villacampa A.J.M., et al.: Cartilagenous grafts in rhinoplasty. *Acta. Otorhinolaryngol. Esp.*, 53: 736, 2002.
- 19- Gibson T. and Davis W.B.: The distortion of autogenous cartilage grafts: Its causes and prevention. *Br. J. Plast. Surg.*, 10: 257, 1957.
- 20- Motoki D.S. and Mulliken J.B.: The healing of bone and cartilage. *Clin. Plast. Surg.*, 17: 527, 1990.
- 21- Bateman N. and Jones N.S.: Retrospective review of augmentation rhinoplasties using autogenous cartilage grafts. *J. Laryngol. Otol.*, 114: 514, 2000.
- 22- Song C., Mackay D.R., Chait L.A., Mander E.K. and Kelly M.A.: Use of costal cartilage cantilever grafts in Negroid rhinoplasties. *Ann. Plast. Surg.*, 27: 201, 1991.
- 23- Collawn S.S., Moore J.R. and Vasconez L.O.: Nasal cartilage grafts: More than a decade of experience. *Plast. Reconstr. Surg.*, 100: 1547, 1997.
- 24- Sheen J.: Approach to alar base resection. In: Rees T.D., Baker D.C. and Tabbal N. (eds.). *Rhinoplasty: Problems and Controversies*. The C.V. Mosby Company. St. Louis, Washington D.C. and Toronto. Chapter 21, p 180, 1988.
- 25- Klabunde E.H. and Falces E.: Incidence of complications in cosmetic rhinoplasties. *Plast. Reconstr. Surg.*, 34: 192, 1964.
- 26- Rees T.D.: Secondary rhinoplasty. In: Masters F.W. and Lewis (eds.). *Masters F.W. and Lewis (eds.). Symposium on aesthetic surgery of the nose, ears and chin*. The C.V. Mosby Company. Saint Louis. Chapter 11, p 58, 1973.
- 27- Peck G.: Nasal tip projection: Goals and maintenance. In: Rees T.D., Baker D.C. and Tabbal N. (eds.). *Rhinoplasty: Problems and Controversies*. The C.V. Mosby Company. St. Louis, Washington D.C. and Toronto. Chapter 43, p 384, 1988.